



Pisco Med Publishing

Endoscopic Injection of Recombinant Human Adenovirus Type 5 Combined with Chemotherapy in the Treatment of Gastric Cancer: A Case Report

Guidong Jiang¹, Doudou Hu², Xiangjun Jiang^{2*}

1. Dalian Medical University, Dalian 116000, China.

2. Qingdao Municipal Hospital, Qingdao 266071, China.

Abstracts: Purpose: To investigate the endoscopic injection of recombinant human adenovirus type 5 (H101) in the treatment of gastric cancer. **Method:** The diagnosis and treatment data of one patient with advanced gastric cancer were collected and discussed. **Result:** The patient, a 51-year-old middle-aged male, was diagnosed with gastric malignant tumor (adenocarcinoma stage IV) with liver metastasis and lymph node metastasis combined with the results of gastroscopy, imaging and pathological examination. The patient underwent endoscopic injection of recombinant human adenovirus type 5 (H101) and chemotherapy. After 4 times of endoscopic treatment, the patient had no serious adverse reactions, pyloric obstruction was relieved, carcinoembryonic antigen was significantly reduced, intragastric ulcerated-like tumor was healed, the range of liver metastases was reduced. In outpatient follow-up, no tumor recurrence or metastasis was found, and the general condition was good. **Conclusion:** Endoscopic injection of recombinant human adenovirus type 5 showed good efficacy and safety and tolerability in patients with advanced gastric cancer. It is worthy of further promotion in clinical practice.

Keywords: Gastric Cancer; Adenovirus; Chemotherapy; Case-Reporting

1. Introduction

Gastric cancer is one of the most common digestive malignancies worldwide. There were 1.08 million new cases globally in 2020. It is the fifth most common cancer and the fourth leading cause of death worldwide.^[1] At present, chemoradiotherapy is the main therapeutic measure to delay the progression of middle and advanced gastric cancer. However, the overall treatment effect was suboptimal. Oncolytic virus treatment is a new therapy of tumor biology and immunotherapy. It uses the virus's ability to replicate to selectively infect and destroy tumor cells while preserving normal cells and tissues.^[2] Recombinant human Adenovirus type 5 injection (H101) is the application of genetic engineering technology to reconstruct human adenovirus type 5. It has achieved some curative effect in the treatment of some middle and advanced malignancies. A case of advanced gastric cancer treated with endoscopic recombinant human adenovirus type 5 (H101) injection combined with SOX regimen in our hospital is reported as follows.

2. Case data

The patient, a 51 years old male, was admitted to our hospital due to abdominal pain for half a month on May 26, 2017. More than 10 days before admission, previous gastroscopy in another hospital suggested that he had gastric mucosal lesions and pyloric obstruction. Pathological examination was performed that he had adenocarcinoma of gastric antrum. Abdominal CT showed that he had gastric cancer in the antrum and gastric horn and multiple liver metastases with intraperitoneal lymph node metastases. He was diagnosed with gastric malignancy (adenocarcinoma stage IV) with liver metastasis and lymph node metastasis. The patient was healthy and had no history of hepatitis or tumor, and no history of drug allergy. The patient vomited at admission and lost 8kg of weight with 1 point according to the Stomach Outlet Obstruction Score System (GOOSS) and 5 points for nutritional risk screening score (NRS-2002). Physical examination on admission showed clear consciousness and general spirit, no obvious abnormality was found in cardiopulmonary percussion and

palpation, the abdomen was flat and soft, stomach type was visible, no mural varicose veins were observed, mild tenderness in the upper abdomen, no rebound pain, no tenderness or rebound pain in the rest of the abdomen, Murphy negative, and negative mobility dullness. The patient underwent a SOX regimen (oxaliplatin 200mg d1 + tiggio 50mg bid) combined with four endoscopic recombinant human type 5 adenovirus (H101)1.5ml multipoint injection). During the treatment, the patient only occasionally had mild abdominal pain and abdominal distension, without nausea, vomiting, fever, anemia and other serious adverse reactions.His GOOSS score was 4, and the NRS-2002 was 1. Abdominal CT showed that the range of multiple liver metastases was reduced and the carcinoembryonic antigen was significantly reduced.The patient was in good mental state, had a fair diet, felt better quality of life, and gained 5kg in weight.Patients were followed up after discharge and regularly reviewed at local hospitals. Due to personal economic reasons, the patients could not continue to receive endoscopic adenovirus injection combined with chemotherapy in our hospital. Specific examination and laboratory tests during hospitalization in our hospital are shown in Table 1. The image data are shown in Figure 1.

3. Conclusion

The incidence and case fatality rate of gastric cancer both ranked the third place among malignant tumors in China.According to global cancer statistics, there were 478,508 new cases of gastric cancer and 373,798 deaths in China in 2020, accounting for 44% and 49% of the world, respectively.^[3]The treatment of gastric cancer includes surgery, chemoradiotherapy, targeted and immunotherapy.At present, it is believed that although the radical resection of early gastric cancer can completely remove the lesion, 30% of the patients will still have local or distal recurrence after surgery.^[4-5]Patients with advanced palliative chemotherapy have many adverse effects, with a 5-year survival rate of 25 – 30%.^[6]Targeted drugs have limited efficacy due to the complex tumor microenvironment, genetic instability, and heterogeneity of HER2 expression in both primary and metastatic sites.^[7]Immunotherapy requires the selection of appropriate patients based on specific molecular markers, and some elderly cancer patients may be affected by immune system dysfunction.^[8]So new treatments for gastric cancer are urgently needed. Oncolytic virus is a new type of tumor immunotherapy, which can change "cold" tumor into "hot" tumor by inducing chemokines and cytokines, promote anti-tumor immune response, and further enhance the efficacy of immunotherapy, with good safety and no serious adverse reactions.

Common complications of advanced gastric cancer include pyloric obstruction, gastrointestinal bleeding, perforation, etc.Pyloric obstruction is more common, which not only seriously affects the quality of life of patients, but also may promote the spread and metastasis of gastric cancer.Current common treatments are surgical procedures and self-expanded metal stenting (SEMS).Although both methods can relieved clinical symptoms, they did not inhibit tumor progression. Complications such as stent migration, tumor stent growth and anastomotic tumor recurrence will occur.^[9]The patient's first gastroscopy revealed a large ulcer-like tumor in the gastric horn with pyloric obstruction, with a GOOSS score of 1. After 4 injections of recombinant human adenovirus type 5 (H101), the gastric horn ulcer-like tumor was healed and pyloric obstruction was relieved by gastroscopy. GOOSS score was 4.The patient was in good mental state and could eat normally without symptoms such as vomiting and food. The weight gain was about 5kg, and the NRS-2002 score was 1.Haemoglobin and albumin levels were also identified as indicators of dietary improvement.^[10]After treatment, hemoglobin, total protein and albumin increased by 12g/L, 6.87g/L and 3.68g/L respectively.It can be concluded that endoscopic adenovirus injection can not only dynamically observe the pathological conditions of gastric lesions, but also directly inject adenovirus into the tumor to inhibit the tumor progression, thereby alleviating pyloric obstruction and improving the quality of life of patients. When necessary, endoscopic hemostasis and pathological biopsy can also be performed.Patients with advanced gastric cancer have a poor prognosis, usually palliative chemotherapy, and the SOX regimen is commonly used in China.However, more adverse reactions appeared, such as anemia, leukopenia, thrombocytopenia, fever, nausea and vomiting.Peripheral sensory neuropathy and oral mucositis also appeared in some studies.^[11,12]In this case, the patient had no above adverse effects during the chemotherapy treatment of H101 injection combined with SOX regimen, with only mild abdominal pain and abdominal distension, and the pain score (NRS) was 1.A study by ZHANG et al found that adverse effects such as nausea, vomiting, constipation, granulocopenia, anemia, and alopecia were less common in single H101 treatment compared with monotherapy, chemotherapy plus H101.^[13]Therefore, H101 injection is currently considered to have

a good safety and tolerability.

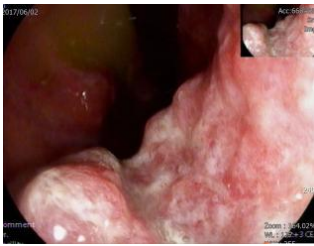Adenovirus (Ads) is a non-enveloped virus with a double stranded DNA genome of about 36KB, which is one of the most studied oncolytic viruses.^[14]Ads monotherapy or combination chemotherapy has been widely used in the treatment of solid tumors such as head and neck tumors, oesophageal cancer, gastric cancer, lung cancer, and liver cancer. A study by CHEN et al showed that rAd-p53 inhibited the growth of gastric cancer cells and that cells with more differentiation were more sensitive to the treatment of rAd-p53.^[15]Rad-p53 is a weakened adenovirus carrying the wild-type p53 gene. Previous studies have shown that rad-p53 inhibits tumor growth, promotes apoptosis and enhances the sensitivity of tumor cells to chemoradiotherapy by inducing the expression of Puma, Bax, Bak and Fas.^[16]Recombinant human adenovirus type 5 (H101) is also a kind of oncolytic adenovirus, but it is relatively poorly studied in gastric cancer. H101 was obtained by genetic engineering techniques for the deletion of some human type 5 adenovirus E1B-55kD protein and the E3 region.^[17]The deletion of E3 fragments can transmit tumor antigen information to the human immune system, activate T lymphocytes, and induce the body to produce an immune response against adenovirus, thus killing tumor cells infected with adenovirus and establishing lasting antitumor immunity. H101 can not replicate in the p53 normal cells, and p53 expression in gastric cancer, so the virus can replicate in the body and infect tumor cells, inhibit the production of vascular endothelial growth factor and the formation of tumor neovascularization, eventually lysis kill tumor cells, release the offspring virus to infection the surrounding tumor cells, thus play the anti-tumor role of targeted killing. H101 can also improve the efficacy of chemoradiotherapy. Therefore, consider that H101 may inhibit tumor progression and prolong the survival cycle of tumor patients through the above mechanisms. In conclusion, endoscopic adenovirus injection can flexibly observe gastric lesions, directly act on the tumor, relieve pyloric obstruction, improve patient quality of life, with no obvious adverse reactions, and good tolerance and safety. However, this paper only discusses a single case and is not extensive. Therefore, H101 needs to be further explored clinically in the treatment of gastric cancer.

Table 1

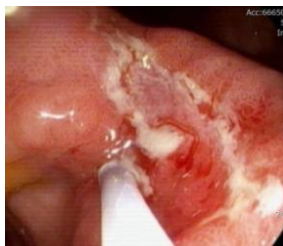result	2017.06.02 (First injection of adenovirus)	2017.06.28 (Second injection of adenovirus)	2017.08.16 (Third injection of adenovirus)	2017.11.15 (Fourth injection of adenovirus)
W.B.C. (10 ⁹ /L)	7.56	4.40	4.31	3.63
neutrophile granulocyte (10 ⁹ /L)	5.24	2.58	2.30	1.96
oxyphorase (g/L)	138	136	140	150
blood cells (10 ⁹ /L)	122	98	106	123
AFP (ng/ml)	1.68	2.59	3.11	2.55
carcinoembryonic antigen (ng/ml)	94.17	254.30	22.29	8.10
CA199(ng/ml)	<0.600	<0.600	<0.600	<0.600
CA125(ng/ml)	18.61	15.69	6.38	5.16
CA724(ng/ml)	NA	2.22	3.25	3.01
ALT(U/L)	38.16	39.10	55.43	19.41
AST(U/L)	58.10	43.65	38.39	22.71
total protein (g/L)	58.69	58.88	66.20	65.56
albumin (g/L)	41.69	40.09	46.77	45.37
total bilirubin (umol/L)	15.60	12.50	15.80	12.60
BRD (umol/L)	4.10	3.40	3.40	2.50
Indirect bilirubin (umol/L)	11.50	9.10	12.40	10.10
creatinine (umol/L)	95.70	75.90	79.34	63.63
usea nitrogen (mmol/L)	7.28	4.62	4.56	7.17

Figure 1

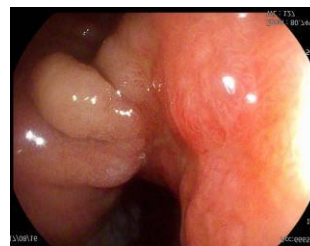Gastroscope



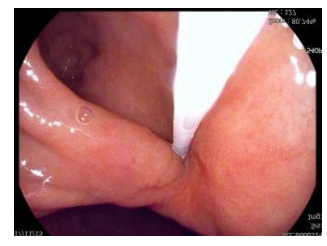First injection of adenovirus



Second injection of adenovirus

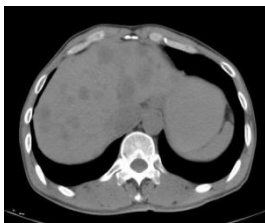

Third injection of adenovirus

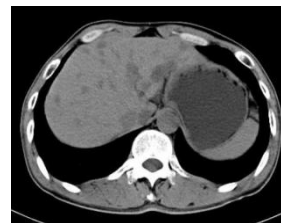

Fourth injection of adenovirus

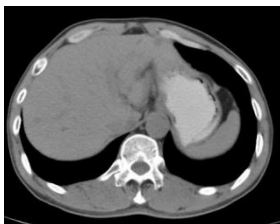CT



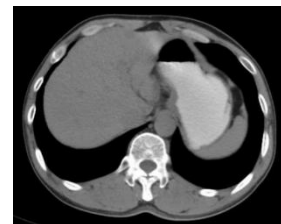
First injection of adenovirus



Second injection of adenovirus



Third injection of adenovirus



Fourth injection of adenovirus

References

- [1] Hyuna Sung, PhD, Jacques Ferlay, MSc, ME, Rebecca L. Siegel, MPH, et al. Global Cancer Statistics 2020: GLOBOCAN Estimates of Incidence and Mortality Worldwide for 36 Cancers in 185 Countries. *CA CANCER J CLIN* 2021; 71: 209–249.
- [2] Rogulski KR, Freytag SO, Zhang K, et al. In vivo antitumor activity of ONYX-015 is influenced by p53 status and is augmented by radiotherapy[J]. *Cancer Res*, 2000, 60(5):1193-1196
- [3] WHO. Globocan 2020 Stomach. In: WHO, Globocan 2020 China. China:International Agency for Research on Cancer. March 2021. Available at:<https://gco.iarc.fr/today/data/factsheets/cancers/7-Stomach-fact-sheet.pdf>.
- [4] Nakagawa N, Kanda M, Ito S, et al. Pathological tumor infiltrative pattern and sites of initial recurrence in stage II/III gastric cancer: propensity score matching analysis of a multi-institutional dataset. *Cancer Med*. 2018;7(12):6020–9.
- [5] Kim JH, Lee HH, Seo HS, et al. Borrmann type 1 Cancer is associated with a high recurrence rate in locally advanced gastric Cancer. *Ann Surg Oncol*.2018;25(7):2044–52.
- [6] Chan BA, Jang RW, Wong RK, Swallow CJ, Darling GE, Elimova E. Improving Outcomes in Resectable Gastric Cancer: A Review of Current and Future Strategies. *Oncology (Williston Park)*. 2016; 30: 635-645.
- [7] Ozge Gumusay, Mustafa Benekli, Ozgur Ekinci, Meltem Baykara, Ahmet Ozet, Ugur Coskun, Umut Demirci, Aytug Uner, Ayse Dursun, Ecine Yesim Atak, Suleyman Buyukberber, Discordances in HER2 status between primary gastric

cancer and corresponding metastatic sites, *Japanese Journal of Clinical Oncology*, Volume 45, Issue 5, May 2015, Pages 416–421,

- [8] Elias R, Karantanos T, Sira E, Hartshorn KL. Immunotherapy comes of age: Immune aging & checkpoint inhibitors. *J Geriatr Oncol*. 2017 May;8(3):229-235. doi: 10.1016/j.jgo.2017.02.001. Epub 2017 Feb 17. PMID: 28223073.
- [9] Saeed SM, Bilal S, Siddique MZ, Saqib M, Shahid S, Ghumman AN, Yusuf MA. Pyloric stent insertion in malignant gastric outlet obstruction: moving beyond palliation. *Ther Adv Gastrointest Endosc*. 2021 Sep 25;14:26317745211047012. doi: 10.1177/ 26317745211047012. PMID: 34595475; PMCID: PMC8477674.
- [10] Kim DY, Moon HS, Kwon IS, Park JH, Kim JS, Kang SH, Lee ES, Kim SH, Lee BS, Sung JK, Jeong HY. Self-expandable metal stent of esophagogastric junction versus pyloric area obstruction in advanced gastric cancer patients: Retrospective, comparative, single-center study. *Medicine (Baltimore)*. 2020 Aug 14;99(33):e21621. doi: 10.1097/MD.00000000000021621. PMID: 32872019; PMCID: PMC7437803.
- [11] Zhong, DT, Wu, RP, Wang, XL, Huang, XB, Lin, MX, Lan, YQ, & Chen, Q, Combination Chemotherapy with S-1 and Oxaliplatin (SOX) as First-Line Treatment in Elderly Patients with Advanced Gastric Cancer; *Pathol. Oncol. Res.* (2015) 21:867–873 DOI 10.1007/s12253-015-9903-1
- [12] Lee KW, Chung IJ, Ryu MH, Park YI, Nam BH, Oh HS, Lee KH, Han HS, Seo BG, Jo JC, Lee HR, Kim JW, Park SR, Cho SH, Kang YK; SOPP study investigators. Multicenter phase III trial of S-1 and cisplatin versus S-1 and oxaliplatin combination chemotherapy for first-line treatment of advanced gastric cancer (SOPP trial). *Gastric Cancer*. 2021 Jan;24(1):156-167. doi: 10.1007/s10120-020-01101-4. Epub 2020 Jun 28. PMID: 32596783.
- [13] Zhang, R, Cui, YX, Guan, X, and Jiang, XJ, A Recombinant Human Adenovirus Type 5 (H101) Combined With Chemotherapy for Advanced Gastric Carcinoma: A Retrospective Cohort Study. *Gastrointestinal Cancers*. published: 09 December 2021 doi: 10.3389/fonc.2021.752504.
- [14] Lobke CM, Hensen, Rob C, Hoeben and Selas TF. Bots. Adenovirus Receptor Expression in Cancer and Its Multifaceted Role in Oncolytic Adenovirus Therapy. *Molecular Sciences. Int. J. Mol. Sci.* 2020, 21, 6828; doi:10.3390/ijms21186828.
- [15] Chen, GX, Zheng, LH, Liu, SY, He, XH., rAd-p53 enhances the sensitivity of human gastric cancer cells to chemotherapy. *World J Gastroenterol* 2011 October 14; 17(38): 4289-4297 ISSN 1007-9327 (print) ISSN 2219-2840 (online).
- [16] Ki, SH, Jeong, S., Park, IS, Lee, DH, Lee, JI, Kwon, KS, Kim, HG, & Shin, YW, Esophageal mucosal metastasis from adenocarcinoma of the distal stomach, *World J Gastroenterol* 2013 June 21; 19(23): 3699-3702.
- [17] Kuball J, Wen SF, Leissner J, Atkins D, Meinhardt P, Schuler M. Successful adenovirus-mediated wild-type p53 gene transfer in patients with bladder cancer by intravesical vector instillation. *J Clin Oncol* 2002; 20: 957-965.